

Neuroimaging in disorders of consciousness: contributions to diagnosis and prognosis

Damian Cruse^{1,2}, Martin M Monti¹ & Adrian M Owen^{1,2}

¹Medical Research Council, Cognition & Brain Sciences Unit, 15 Chaucer Road, Cambridge, CB2 7EF, UK

²Centre for Brain and Mind, University of Western Ontario, London, ON, N6A 5B7, Canada

³Author for correspondence: Centre for Brain & Mind, Natural Sciences Centre, Room 237, University of Western Ontario, London, ON, N6A 5B7, Canada ■ dcruse@uwo.ca

Conventional assessment of the level of awareness that is retained by a patient with a disorder of consciousness following a brain injury is made on the basis of exhibited behaviors. This is particularly challenging for clinicians who must decide whether a certain behavior, which might be inconsistent or incomplete, reflects a conscious or an unconscious process. These assessments are not only highly subjective, but also dependent upon the ability of the patient to produce an appropriate motor response. Recent developments in neuroimaging techniques can provide a measure of the levels of awareness that these patients may retain, and importantly, they overcome the necessity for these patients to produce detectable movements by instead relying on their adopting appropriate 'mind-sets' as instructed by the task. In this article, we review recent advances in this field and discuss how they may accompany behavioral assessments in future in order to provide diagnostic and prognostic information.

The process of diagnosing a patient with a disorder of consciousness (DOC), such as the vegetative state (VS) or minimally conscious state (MCS), is a challenging one. Unlike other neurological conditions, these DOCs are not defined by a particular pathology or neural marker, but must instead be distinguished and diagnosed on the basis of clinical history and careful behavioral assessment. Such assessments typically rely on repeated daily examinations of spontaneous and elicited behavior in response to multisensory stimulation, in accordance with specific scales such as the Sensory Modality Assessment and Rehabilitation Technique (SMART) [1], the JFK Coma Recovery Scale – Revised (CRS-R) [2] or the Wessex Head Injury Matrix (WHIM) [3]. In all cases, a diagnosis of VS is only made when a state of 'wakefulness without awareness' [4] is observed, which in turn depends on three defining features [5]:

- No evidence of awareness of the self or the environment;
- No evidence of sustained, reproducible, purposeful or voluntary response to auditory, tactile or noxious stimuli;
- No evidence of language comprehension or expression.

In time, a small number of VS patients may go on to regain some degree of awareness, progressing to MCS, while others may progress directly from a comatose state to MCS. In contrast to the VS,

minimally conscious patients show inconsistent but reproducible evidence of awareness of themselves and their environment, in as much as they can exhibit sustained, reproducible or voluntary behavioral responses to sensory stimulation (e.g., visual, auditory, tactile or nociceptive).

While these scales all involve detailed behavioral assessments, they are nevertheless ultimately scored on the basis of the clinicians' subjective opinions of the patients' responses. This subjectivity of assessment may lead to high levels of misdiagnosis by those who are less experienced in their use, or indeed by experienced assessors when behavioral signs are minimal or entirely absent. Perhaps unsurprisingly, it has been reported in a number of studies that up to 43% of patients with a diagnosis of VS were in fact misdiagnosed [6–8].

The reliance upon the absence of overt motor responses in order to reach a diagnosis of VS meets a considerable challenge when the cases of individuals with 'locked-in syndrome' are considered. These individuals may lose all but some minor motor abilities as a result of acute injury (usually to the brain stem) and yet retain complete awareness of themselves and their surroundings. Such patients may then, under subjective behavioral assessment alone, be assumed to be in a VS if their retained motor responses go unnoticed – a diagnosis completely at odds with their internal mental state. Clearly, the implications of these differential diagnoses on patients and their families are profound.

Keywords

- awareness ■ consciousness
- EEG ■ event-related potential ■ functional MRI
- minimally conscious state
- vegetative state

future medicine part of fsg

Recent advances in neuroimaging technology may provide one solution to the reliance upon behavioral responses when assessing patients with DOCs. In 2006, Owen and colleagues recharacterized the way in which an individual can be said to respond to command by including the hemodynamic response of the brain, as detected with functional MRI (fMRI) [9]. In that study, a patient who appeared to be in a VS was asked to perform two mental imagery tasks – imagining playing tennis and imagining walking through the rooms of her house – that are associated with the differential activation of a number of distinct brain regions. The resulting patterns of brain-responses, which were entirely comparable with those observed in healthy, awake, control participants performing these same imagery tasks to command, allowed Owen and colleagues to conclude that the patient was responding to command and therefore retained a level of awareness that was not apparent from her (lack of) behavior. This result served to highlight the potential contribution of neuroimaging methods to diagnosis of the level of awareness in patients with DOCs. This article presents a review of recent developments in this field and considers how they may contribute to the diagnoses and prognoses of patients with DOCs.

Passive neural responses to stimulation: functional MRI & EEG

One approach to assessing the cognitive abilities of DOC patients with neuroimaging is by means of passive stimulation (i.e., when there is no task to be performed on the part of the patient). Historically, the use of functional neuroimaging in studies of patients with DOCs began with $H_2^{15}O$ PET. In the first study of its kind, de Jong and colleagues measured regional cerebral blood flow in a VS patient during an auditorily presented story told by his mother [10]. When compared with nonword sounds, activation was observed in the anterior cingulate and temporal cortices, possibly reflecting emotional processing of the contents or tone of the mother's speech. The following year, Menon and colleagues observed robust activity in the right fusiform gyrus, the so-called 'human face area', in a patient diagnosed as vegetative who was presented with familiar faces [11].

In recent years, the field has shifted toward the use of fMRI due to its increased statistical power and improved temporal and spatial resolution [12]. With this technique, differential responses to speech and nonspeech stimuli have been observed in the so-called 'language centers'

of the brain in patients with DOCs [13,14]. It has also been reported that a group of DOC patients demonstrated greater activation of the anterior cingulate cortex when hearing their own name relative to unfamiliar names [15]. Similar contrasts have revealed activations in associative areas of the temporal lobes [16] and medial prefrontal cortex [17] in some patients with DOCs. EEG and event-related potentials (ERPs) have revealed similar results. For example, when presented infrequently among tones and other names, a reliable mismatch negativity to their own name has been observed in the ERPs of some coma, VS and MCS patients, demonstrating some selectivity of those patients' neural responses to hearing their own name [18].

In the largest study of passive stimulation to date, the fMRI activations of 41 patients with DOCs were assessed with a hierarchical series of language paradigms that increased systematically in the complexity of the processing required [19]. At the most basic level, a contrast was made between responses to simple nonlinguistic sounds and the response to the absence of sound in order to assess basic acoustic processing. At its highest level, contrasts were made between responses to sentences containing semantically ambiguous words (e.g., the creak/creek came from a beam in the ceiling/sealing) and those containing no semantically ambiguous words (e.g., her secrets were written in her diary) in order to reveal the brain activity associated with the selection of the appropriate meaning of these words and therefore of language comprehension. A total of 19 of the patients (almost 50%) who had been diagnosed as VS or MCS showed normal or near-normal responses in the low-level acoustic contrast (sound vs no sound) and in the mid-level speech perception contrast (speech vs nonspeech sounds). Four patients, two of whom were behaviorally considered to be in a VS, exhibited normal brain activity in the highest-level contrast designed to isolate neural processes involved in speech comprehension.

While the observation of patterns of brain activity comparable with those seen in healthy controls during passive stimulation is an interesting one, to what extent can we conclude that this indicates awareness of the contents of the speech on the part of the patient, rather than simply an automatic response? What diagnostic conclusions can really be drawn? Indeed, many aspects of human cognition, including semantic processing, can go on in the absence of awareness [20,21]. Although this does not mean that DOC patients who show responses to linguistic

stimuli are not aware, it does preclude the possibility that one might unequivocally conclude that they are. One means of teasing apart these possibilities is to investigate the ways in which the brains of sedated healthy control participants respond during these passive paradigms. Davis and colleagues recently used the same hierarchical language paradigm described previously with healthy participants who were tested under three levels of sedation, including a deep level in which no conversational responses were observed and the individual could only be roused by loud command [22]. Interestingly, the differential neural processing of speech relative to nonspeech stimuli remained intact, even at this highest level of sedation, suggesting a level of automaticity in the selective processing of speech over other sounds. However, the normal patterns of activity observed in the contrast designed to investigate language comprehension (sentences containing semantically ambiguous words vs those that do not) were markedly absent even at light sedation. Together, these findings suggest that DOC patients who demonstrate comparable activations at this highest level of contrast may retain a level of conscious awareness, while those showing activations in the lower-level contrasts only may be no more consciously aware than an individual who is heavily sedated.

Structural & functional connectivity

High-resolution MRI techniques have allowed for the investigation of those brain structures that are most important for determining the level of awareness that is demonstrated behaviorally by patients with DOCs. In a recent study, Fernandez-Espejo and colleagues observed significant reductions in the thalamic volume of patients in a VS or MCS [23]. Interestingly, their analysis technique allowed the authors to investigate the particular regions of the thalami that were most affected, and they observed atrophy predominantly in the dorsal body of the thalamus for MCS patients, with much more widespread bilateral atrophy in the group of VS patients.

One recent focus has been on investigations of the so-called 'default mode network' (DMN) of brain regions [24], including the precuneus, temporo-parietal junction and medial prefrontal cortex, which show idling activity when an individual is at rest and relative deactivations when engaged in a task. Resting state data, similarly to passive stimulation data, are very easy to obtain in VS and MCS patients as it does not require the performance of any task on the part of the participant under study.

Reductions in the functional connectivity of regions of the DMN have been observed in non-pathological states of altered consciousness, such as anesthesia [25] (see [26] for a review). In the first investigation of the DMN in VS patients, reduced functional connectivity within these regions was observed, predominantly in the right hemisphere [27]. Boly and colleagues [28] described a VS patient with preserved cortico-cortical blood oxygen level-dependant connectivity within the DMN, but absent cortico-thalamic connectivity, highlighting the importance of the thalami in behavioral demonstrations of awareness. In a second study, resting-state connectivity was investigated using probabilistic independent component analysis in 14 noncommunicative brain-damaged patients and 14 healthy controls [29]. As speculated by Cauda and colleagues (although their low patient numbers did not allow them to be more definite) [27], the level of functional connectivity within DMN regions was found to be negatively correlated with behavioral signs of awareness, with VS patients showing reduced connectivity relative to MCS patients, both of which were reduced relative to healthy controls [29].

Another significant development during the last decade has been methods for assessing the structural connectivity of the brain (see [30] for a comprehensive discussion of some of these techniques). Diffusion tensor imaging (DTI) is a noninvasive magnetic resonance technique that allows examination of white matter fiber tracts *in vivo*. To date, detailed histopathological studies have shown no pathological distinctions between the VS and MCS [31]. Coleman and colleagues, as part of a multimodal approach to the assessment of a patient in a MCS, observed reduced fractional anisotropy – a measure of the diffusion of water along white matter fiber tracts and therefore of anatomical connectivity – in comparison with healthy controls, indicating widespread loss of white matter integrity [32]. This was accompanied by a significantly increased apparent diffusion coefficient in comparison with healthy controls, suggesting a loss of cortico-cortical connectivity. A prospective cohort study of serial DTI following severe traumatic brain injury and coma also found that cognitive and behavioral improvements were correlated with recovery of normal-to-supranormal fractional anisotropy in preselected white matter regions [33], suggesting possible axonal regrowth accompanying these behavioral improvements.

Based on DTI measures of the integrity of subcortical white matter and the thalami, it has been recently demonstrated that it is possible to

classify DOC patients into either a VS or MCS with an accuracy of 95% [34]. Not only do these findings together highlight the importance of particular structures such as the thalamus and its connectivity with the cortex in underpinning awareness, they also provide a potential diagnostic and prognostic tool based upon the particular structural features that remain preserved. The increased routine acquisition of DTI and resting-state data in future will allow for an investigation of the utility of such information.

From passive response to willful modulation

As discussed previously, brain responses to stimulation may occur automatically in patients with DOCs. Such results do not, in of themselves, run contrary to the behavioral diagnoses since conscious awareness may not be necessary for their generation. However, what if an element is added to a task design that requires a conscious response on the part of the patient in order to produce appropriate patterns of neural activity? This might show an ability to respond to command and therefore be at odds with the behavioral diagnosis.

The aforementioned study by Owen and colleagues provided such evidence in a VS patient who was able to generate consistent fMRI responses during two mental imagery tasks; evidence of command following that was entirely inconsistent with the behavioral diagnosis [9]. In recent years, a number of similar tasks that require volitional 'behavior' on the part of the patient have been developed.

Monti and colleagues contrasted the hemodynamic response during a task in which patients were instructed to listen passively to a stream of words (common nouns) with that during a task in which they were instructed to count the number of times a target word was heard [35]. An MCS patient produced activations in a frontoparietal network of regions that were comparable with those observed in healthy control participants. Similarly, using ERPs, Schnakers and colleagues were able to demonstrate command following in a task in which, in half of the blocks, patients were instructed to count the number of instances of their own name, in contrast to passive listening in the remaining blocks [36]. Similarly to healthy control participants, a group of MCS patients demonstrated reliably larger P3 ERP components, which are linked to target detection, during the active counting task. Since the only aspect that differed between the two conditions in both the fMRI and ERP

tasks was the patient's intention (to count or to listen), as guided by the prior instruction, it was possible to infer that these patients could follow commands and were therefore, according to universally accepted clinical guidelines, conscious and aware. By contrast, overt (motor) forms of command following were, at best, inconsistent when the patients were tested behaviorally.

The potential for functional neuroimaging techniques to benefit patients in a more direct way was recently demonstrated by Monti and colleagues who mapped the two mental imagery tasks employed previously by Owen and colleagues (playing tennis and navigating around a house [9]) onto the responses 'yes' and 'no'. Patients were instructed to perform one imagery task to respond 'yes' and the other to respond 'no' [37]. Remarkably, a patient who had been repeatedly diagnosed as being in a VS over a 5-year period was able to respond correctly to a series of autobiographical yes/no questions using this method. This is the first time that two-way communication has been demonstrated with such a patient without the production of overt behavior. Such a result also shows that the patient was not only aware, but that many of his higher cognitive functions were largely intact (FIGURE 1).

Implications for diagnosis & prognosis

In severe brain injury, when the request to perform a movement is followed by an appropriate motor response, the diagnosis can change from a VS to MCS due to the presence of overt evidence of awareness. By analogy, if the request to activate a particular brain region by imagining a particular movement is followed by an appropriate brain response, should that response not be given equal weight? Skeptics may argue that brain responses are somehow less physical, reliable or immediate than motor responses but, as is the case with behavioral assessments of motor responses in this patient group, these arguments can be dispelled with careful measurement, replication, and objective verification. For example, if a patient who was assumed to be unaware raised his/her hand to command on just one occasion, there would remain some doubt as to the presence of awareness, given the possibility that this movement was a chance occurrence coincident with the instruction. However, if that same patient were able to repeat this response to command on ten occasions, there would remain little doubt that the patient was aware. Indeed, the JFK CRS-R behavioral score requires a patient to move to auditory command on only three out of four occasions to be considered MCS rather

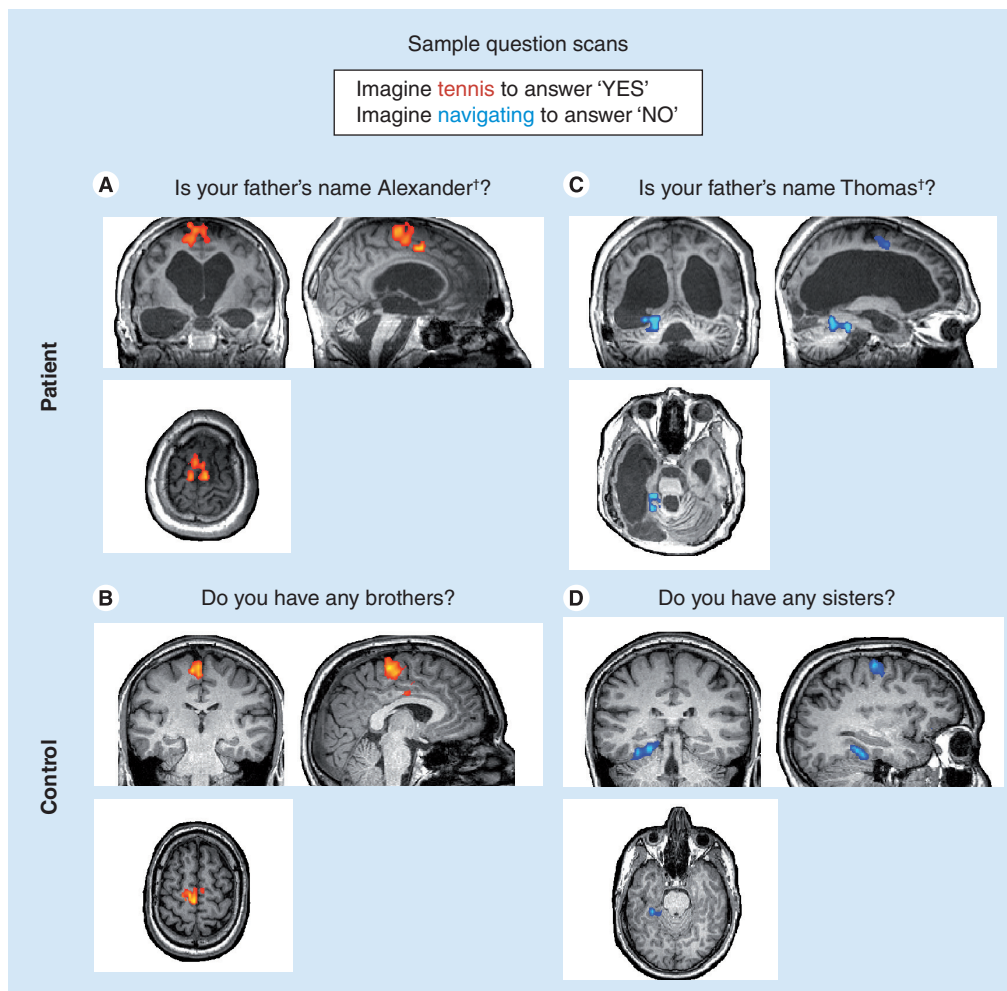


Figure 1. Communicating with a patient who was assumed to be in a vegetative state for 5 years. Imaging results are shown from two sample question scans for the patient and a healthy volunteer. (A) and (B) depict two question scans indicating a 'yes' response. (C) and (D) depict two question scans indicating a 'no' response. The names used in the questions have been changed to protect the privacy of the patients.

[†]Names have been changed to protect the identity of those involved.

Reproduced with permission from [37].

than VS [2]. By the same token, if that patient was able to activate appropriate regions of his/her brain in response to command (e.g., by being told to imagine particular movements) and was able to do this on every one of, say, ten trials, would we not have to accept that this patient was consciously aware?

Therefore, what are the implications for the diagnoses of those patients reported by Owen and colleagues [9] and Monti and colleagues [37] who were able to produce consistent neural responses to command? Clearly, the clinical diagnoses based on behavioral assessments were inaccurate in the sense that they did not accurately reflect the patients' internal states of awareness. However, these patients were not misdiagnosed in the sense that no behavioral marker of awareness was missed. A crucial step in the

quest to establish real communication in a non-responsive patient is first to establish that they are aware and can make responses by modulating brain activity (which can then be marshaled for use in a communication device). While this neural 'behavior' does not alter the patients' formal diagnoses at present, it demonstrates a level of responsivity that could not be revealed by behavioral examinations alone and provides information that is useful both for families (to know that their loved one is aware) and for the medical team (to know that the patient is aware and therefore may benefit from further efforts to engage in 'communication' with them). These assessment methods may also provide important additional information (e.g., regarding improvement or deterioration) in patients treated with experimental brain stimulation and other

the use of neuroimaging techniques alongside conventional behavioral assessments in patients with DOCs.

Conclusion & future perspective

It must be noted that the interpretation of neuroimaging findings is not without its challenges. Acquiring and analyzing fMRI data is especially difficult and complicated in this patient population [47]. In addition, both neuroanatomy and functional neuroanatomy may be severely altered and have undergone some amount of functional remapping in these patients and will therefore affect the interpretability of neuroimaging data, especially when using healthy volunteers as a benchmark. An important issue also relates to the interpretation of negative findings. It is possible for neuroimaging studies to yield no evidence of differential neural activity even in healthy controls, especially on an individual subject basis, due to the reduced statistical power to detect any differences that accompany such comparisons. As with behavioral assessment, repeated scanning at different times of day can help rule out the possibility that, for instance,

the patient was asleep at the time of the previous negative scan. The continued development of a battery of tasks that involve stimuli from different modalities and measurements from multiple neuroimaging modalities (e.g., fMRI, EEG/ERP or near-infrared spectroscopy) will also help to increase the number of opportunities that a patient may have to be able to produce an appropriate neural response when they are able to. For instance, a behaviorally vegetative patient with a lesion to their supplementary motor area (SMA) will probably be unable to produce appropriate activations of their SMA when instructed to imagine particular movements, but may be able to demonstrate a level of awareness in a (non-SMA-dependent) task that involves target detection.

The further development of paradigms that employ neuroimaging methods such as EEG or near-infrared spectroscopy is also of particular importance in this patient group due to the considerably reduced cost and improved portability of such methods when compared with MRI. With such techniques, a greater proportion of patients can be assessed, including those who

Executive summary

The problem of misdiagnosis

- At present, diagnoses of the vegetative state (VS) and the minimally conscious state (MCS) are made on the basis of subjective behavioral assessments of motor responses.
- Recent advances in neuroimaging may provide a means of more accurately assessing a patient's state of awareness than can be provided by behavioral assessment alone.

Passive neural responses to stimulation

- Patients in a VS and MCS have been shown to demonstrate neural responses comparable with healthy controls with a number of different types of stimuli, including faces and speech.
- Some patients have even demonstrated neural responses suggestive of language comprehension.

Structural & functional connectivity

- The level of functional connectivity within regions of the default mode network has been shown to be negatively correlated with behavioral signs of awareness in this patient group.
- Damage to the thalami and a widespread loss of white matter integrity have been observed in this patient group, the extent of which can also be used to classify patients into VS or MCS with an accuracy of 95%.

From passive response to willful modulation

- Functional MRI has allowed the remarkable two-way communication with a patient who had been behaviorally considered to be in a VS.

Implications for diagnosis & prognosis

- The extent to which a patient's brain responds to linguistic stimuli in a hierarchical functional MRI paradigm has been shown to be predictive of their behavioral recovery 6 months later.
- Activation of higher-level associative cortices as detected by PET has also been shown to predict recovery from VS with 93% specificity and 69% sensitivity.

Future perspective

- The future development of a battery of neuroimaging tasks that allow these patients opportunities to demonstrate their awareness where it is retained is vital for the accurate assessment of these patients, alongside conventional behavioral tests.
- The further standardized use of neuroimaging with these patients will also allow investigations of the prognostic contributions these data may make.
- In future, EEG may offer a brain-computer interface for some of these patients to communicate, despite being behaviorally unable to do so.

may not have access to an MRI owing to geographic, financial or physical (i.e., having metal plates or pins) reasons. Broadening the availability of these measures will have clear implications for both patients and caregivers.

The finding of Monti and colleagues that it is possible to communicate with behaviorally vegetative patients using neuroimaging [37] has also opened a door into a world of possibilities for the development of ways with which to provide some communicative abilities to those (apparently) VS or MCS patients who may retain sufficient cognitive abilities to do so. It is clear that an fMRI-based task is not going to be able to provide such a solution for the majority of patients due to the expense of MRI scanning and the frequency with which these patients will have to access an MRI scanner. There is already an extensive body of research that has shown that sophisticated EEG-based brain–computer interfaces can allow physically impaired individuals a degree of control over computerized and

mechanical devices [48]. The relatively lower cost of the EEG method and its indifference towards metal implants (e.g., pins and plates) that would preclude an individual from ever entering an MRI scanner, coupled with the existing EEG brain–computer interfaces literature, clearly point to the future potential of the EEG method in this patient group. While technically challenging, recent preliminary results suggest that this potential may soon be realized [49].

Financial & competing interests disclosure

This research was supported by funding from the Medical Research Council (U.1055.01.002.00007.01 and U.1055.01.002.00001.01) and the James S McDonnell Foundation. The authors have no other relevant affiliations or financial involvement with any organization or entity with a financial interest in or financial conflict with the subject matter or materials discussed in the manuscript apart from those disclosed.

No writing assistance was utilized in the production of this manuscript.

Bibliography

Papers of special note have been highlighted as:

▪ of interest

▪▪ of considerable interest

- Gill-Thwaites H, Munday R: The Sensory Modality Assessment and Rehabilitation Technique (SMART): a valid and reliable assessment for vegetative state and minimally conscious state patients. *Brain Inj.* 18(12), 1255–1269 (2004).
- Giacino JT, Kalmar K, Whyte J: The JFK Coma Recovery Scale-Revised: measurement characteristics and diagnostic utility. *Arch. Phys. Med. Rehabil.* 85(12), 2020–2029 (2004).
- Shiel A, Horn SA, Wilson BA, Watson MJ, Campbell MJ, McLellan DL: The Wessex Head Injury Matrix (WHIM) main scale: a preliminary report on a scale to assess and monitor patient recovery after severe head injury. *Clin. Rehabil.* 14(4), 408–416 (2000).
- Jennett B, Plum F: Persistent vegetative state after brain damage. A syndrome in search of a name. *Lancet* 1(7753), 734–737 (1972).
- The vegetative state: guidance on diagnosis and management. *Clin. Med.* 3(3), 249–254 (2003).
- Schnakers C, Vanhaudenhuyse A, Giacino J *et al.*: Diagnostic accuracy of the vegetative and minimally conscious state: clinical consensus versus standardized neurobehavioral assessment. *BMC Neurol.* 9, 35 (2009).
- Andrews K, Murphy L, Munday R, Littlewood C: Misdiagnosis of the vegetative state: retrospective study in a rehabilitation unit. *BMJ* 313(7048), 13–16 (1996).
- Childs NL, Mercer WN, Childs HW: Accuracy of diagnosis of persistent vegetative state. *Neurology* 43(8), 1465–1467 (1993).
- Owen AM, Coleman MR, Boly M, Davis MH, Laureys S, Pickard JD: Detecting awareness in the vegetative state. *Science* 313(5792), 1402 (2006).
- de Jong BM, Willemsen ATM, Paans AMJ: Regional cerebral blood flow changes related to affective speech presentation in persistent vegetative state. *Clin. Neurol. Neurosurg.* 99(3), 213–216 (1997).
- Menon DK, Owen AM, Williams EJ *et al.*: Cortical processing in persistent vegetative state. *Lancet* 352(9123), 200 (1998).
- Owen AM, Epstein R, Johnsrude IS: fMRI: applications to cognitive neuroscience. In: *Functional Magnetic Resonance Imaging: An Introduction to Methods*. Jezzard P, Mathews PM, Smith SM (Eds). Oxford University Press, UK, 311–327 (2001).
- Fernandez-Espejo D, Junque C, Vendrell P *et al.*: Cerebral response to speech in vegetative and minimally conscious states after traumatic brain injury. *Brain Inj.* 22(11), 882–890 (2008).
- Fernandez-Espejo D, Junque C, Cruse D *et al.*: Combination of diffusion tensor and functional magnetic resonance imaging during recovery from the vegetative state. *BMC Neurol.* 10, 77 (2010).
- Qin P, Di H, Liu Y *et al.*: Anterior cingulate activity and the self in disorders of consciousness. *Hum. Brain Mapp.* 31(12), 1993–2002 (2010).
- Di HB, Yu SM, Weng XC *et al.*: Cerebral response to patient's own name in the vegetative and minimally conscious states. *Neurology* 68(12), 895–899 (2007).
- Staffen W, Kronbichler M, Aichhorn M, Mair A, Ladurner G: Selective brain activity in response to one's own name in the persistent vegetative state. *J. Neurol. Neurosurg. Psychiatry* 77(12), 1383–1384 (2006).
- Qin P, Di H, Yan X *et al.*: Mismatch negativity to the patient's own name in chronic disorders of consciousness. *Neurosci. Lett.* 448(1), 24–28 (2008).
- Coleman MR, Davis MH, Rodd JM *et al.*: Towards the routine use of brain imaging to aid the clinical diagnosis of disorders of consciousness. *Brain* 132(Pt 9), 2541–2552 (2009).
- **Using a large cohort of patients, provides one of the most robust demonstrations of the utility of functional neuroimaging in prognostic judgments reported so far.**
- Schacter DL: Priming and multiple memory systems: perceptual mechanisms of implicit memory. In: *Memory Systems*. Schacter DL, Tulving E (Eds). MIT Press, MA, USA, 233–268 (1994).
- Dehaene S, Naccache L, Le Clecq HG *et al.*: Imaging unconscious semantic priming. *Nature* 395(6702), 597–600 (1998).
- Davis MH, Coleman MR, Absalom AR *et al.*: Dissociating speech perception and comprehension at reduced levels of awareness. *Proc. Natl Acad. Sci. USA* 104(41), 16032–16037 (2007).

23. Fernandez-Espejo D, Junque C, Bernabeu M, Roig-Rovira T, Vendrell P, Mercader JM: Reductions of thalamic volume and regional shape changes in the vegetative and the minimally conscious states. *J. Neurotrauma* 27(7), 1187–1193 (2010).
24. Gusnard DA, Raichle ME: Searching for a baseline: functional imaging and the resting human brain. *Nat. Rev. Neurosci.* 2(10), 685–694 (2001).
25. Peltier SJ, Kerssens C, Hamann SB, Sebel PS, Byas-Smith M, Hu XP: Functional connectivity changes with concentration of sevoflurane anesthesia. *Neuroreport* 16(3), 285–288 (2005).
26. Boly M, Phillips C, Tshibanda L *et al.*: Intrinsic brain activity in altered states of consciousness: how conscious is the default mode of brain function? *Ann. NY Acad. Sci.* 1129, 119–129 (2008).
27. Cauda F, Micon BM, Sacco K *et al.*: Disrupted intrinsic functional connectivity in the vegetative state. *J. Neurol. Neurosurg. Psych.* 80(4), 429–431 (2009).
28. Boly M, Tshibanda L, Vanhaudenhuyse A *et al.*: Functional connectivity in the default network during resting state is preserved in a vegetative but not in a brain dead patient. *Hum. Brain Mapp.* 30(8), 2393–2400 (2009).
29. Vanhaudenhuyse A, Noirhomme Q, Tshibanda LJF *et al.*: Default network connectivity reflects the level of consciousness in non-communicative brain-damaged patients. *Brain* 133, 161–171 (2010).
30. Tshibanda L, Vanhaudenhuyse A, Galanaud D, Boly M, Laureys S, Puybasset L: Magnetic resonance spectroscopy and diffusion tensor imaging in coma survivors: promises and pitfalls. *Prog. Brain Res.* 177, 215–229 (2009).
31. Jennett B, Adams JH, Murray LS, Graham DI: Neuropathology in vegetative and severely disabled patients after head injury. *Neurology* 56(4), 486–490 (2001).
32. Coleman MR, Bekinschtein T, Monti MM, Owen AM, Pickard JD: A multimodal approach to the assessment of patients with disorders of consciousness. *Prog. Brain Res.* 177, 231–248 (2009).
33. Sidaros A, Engberg A, Sidaros K *et al.*: Diffusion tensor imaging during recovery from severe traumatic brain injury and relation to clinical outcome: a longitudinal study. *Brain* 131, 559–572 (2008).
34. Fernandez-Espejo D, Bekinschtein T, Monti MM *et al.*: Diffusion weighted imaging distinguishes the vegetative state from the minimally conscious state. *Neuroimage* 54(1), 103–112 (2011).
35. Monti MM, Coleman MR, Owen AM: Executive functions in the absence of behavior: functional imaging of the minimally conscious state. *Prog. Brain Res.* 177, 249–260 (2009).
36. Schnakers C, Perrin F, Schabus M *et al.*: Voluntary brain processing in disorders of consciousness. *Neurology* 71(20), 1614–1620 (2008).
- **One of the first demonstrations of the utility of EEG in the assessment of patients with disorders of consciousness, something that needs to be continually developed so that all patients – even those who do not have access to an MRI – may have the opportunity to demonstrate their awareness.**
37. Monti MM, Vanhaudenhuyse A, Coleman MR *et al.*: Willful modulation of brain activity in disorders of consciousness. *N. Engl. J. Med.* 362(7), 579–589 (2010).
- **Demonstrates that two-way communication with a behaviorally nonresponsive patient is possible and has opened the door to the development of more sophisticated devices in the future that may allow for regular communication with more of these patients.**
38. Canavero S, Massa-Micon B, Cauda F, Montanaro E: Bifocal extradural cortical stimulation-induced recovery of consciousness in the permanent post-traumatic vegetative state. *J. Neurol.* 256(5), 834–836 (2009).
39. *Textbook of Therapeutic Cortical Stimulation.* Canavero S (Ed.). Nova Science Inc., NY, USA (2009).
40. Whyte J, Gosseries O, Chervoneva I *et al.*: Predictors of short-term outcome in brain-injured patients with disorders of consciousness. *Prog. Brain Res.* 177, 63–72 (2009).
41. Katz DI, Polyak M, Coughlan D *et al.*: Natural history of recovery from brain injury after prolonged disorders of consciousness: outcome of patients admitted to inpatient rehabilitation with 1–4 year follow-up. *Prog. Brain Res.* 117, 73–88 (2009).
42. Azouvi P, Vallat-Azouvi C, Belmont A: Cognitive deficits after traumatic coma. *Prog. Brain Res.* 117, 89–110 (2009).
43. Zasler ND: Long-term survival after severe TBI: clinical and forensic aspects. *Prog. Brain Res.* 117, 111–124 (2009).
44. Di H, Boly M, Weng X, Ledoux D, Laureys S: Neuroimaging activation studies in the vegetative state: predictors of recovery? *Clin. Med.* 8(5), 502–507 (2008).
45. Babiloni C, Sara M, Vecchio F *et al.*: Cortical sources of resting-state α rhythms are abnormal in persistent vegetative state patients. *Clin. Neurophysiol.* 120(4), 719–729 (2009).
46. Schnakers C, Ledoux D, Majerus S *et al.*: Diagnostic and prognostic use of bispectral index in coma, vegetative state and related disorders. *Brain Inj.* 22(12), 926–931 (2008).
47. Giacino JT, Hirsch J, Schiff N, Laureys S: Functional neuroimaging applications for assessment and rehabilitation planning in patients with disorders of consciousness. *Arch. Phys. Med. Rehabil.* 87(12 Suppl. 2), S67–S76 (2006).
48. Kubler A, Neumann N: Brain–computer interfaces – the key for the conscious brain locked into a paralyzed body. *Prog. Brain Res.* 150, 513–525 (2005).
49. Cruse D, Bekinschtein TA, Monti MM, Owen AM: Detecting awareness in the vegetative state with EEG. Presented at: 16th Annual Meeting of the Organization for Human Brain Mapping, Barcelona, Spain, 6–10 June 2010.